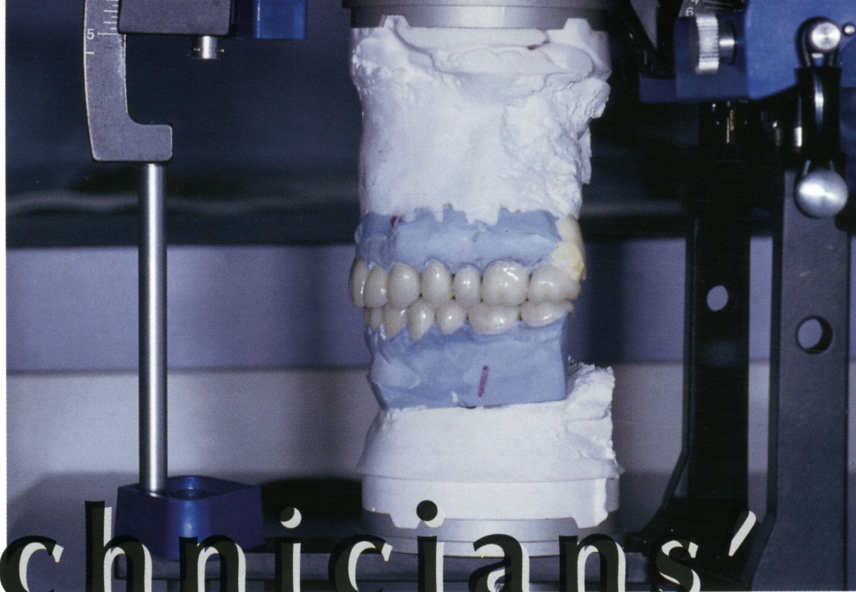


# lab technicians'

## information



by  
John Haupt, F.A.A.C.D.

John Haupt is an Accredited member and Fellow of the AACD. He has served on the Board of Directors, and is a faculty member of Orognathic Bioesthetic International. He owns a family-operated dental laboratory in Brea, California.

### A TEAM APPROACH TO FULL MOUTH REJUVENATION

An escalating interest in restoring anterior worn dentition seems to be the new “hot topic” among dental professionals. With the introduction of many different all-ceramic restorative materials that advocate less invasive preparations, it appears that clinicians are more willing to prep anterior teeth today than they were when only porcelain fused to metal were available.

---

*Rather than looking for solutions with a “super strong” restorative material, perhaps the cause of the accelerated tooth wear should be addressed.*

---

When the first porcelain veneers were introduced in the mid 1980s, they were used primarily for color changes or diastema closures, whereas today requests for all-ceramic restorations range from strictly cosmetic enhancements to restorative lengthening of teeth.

The strength of the ceramic material has not significantly increased from the “early days,” but the strength that is now expected of the materials has increased beyond what one might consider reasonable.

Rather than looking for solutions with a “super strong” restorative material, perhaps the cause of the accelerated tooth wear should be addressed.

Harmonious long-term function and reliability depends upon the cohesive relationship between the anterior and posterior dentition, the dentogingival complex, the temporomandibular joints (TMJ) and the patient’s neuromusculature system.<sup>1</sup>

This article attempts to define the roles of these elements and to demonstrate their rehabilitation through a unified team approach between the dentist and the dental technician.



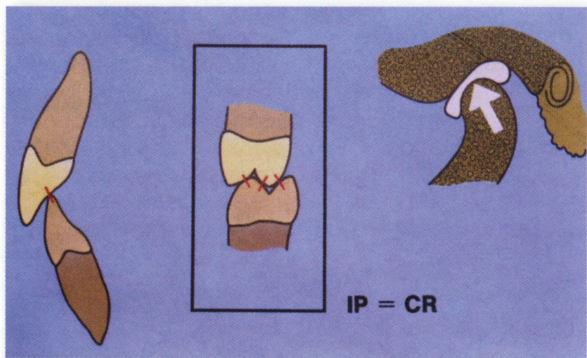


Figure 1: Ideally, all of the teeth should be hitting evenly when the condyles are in CR position.

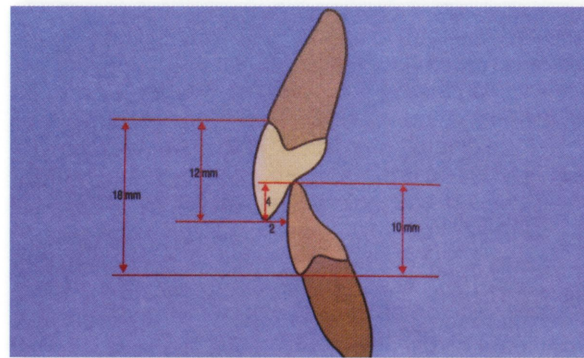


Figure 2: The length of the anterior teeth should be long enough to facilitate complete posterior clearance in protrusive guidance. This may be accomplished through proper axial inclination of the anterior teeth and through horizontal overlap of 2 mm and vertical overlap of 3-4 mm.



Figure 3: Severe wear and loss of vertical dimension.

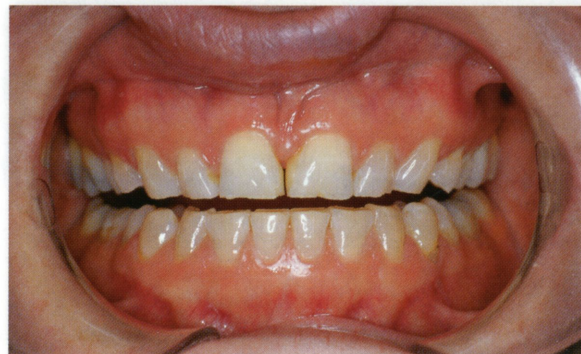

Figure 4: No cuspid guidance.

The success of functional and esthetic dentistry depends upon the clinician's and technician's understanding of natural tooth morphology, tooth position, and gingival contours; and the influence of these elements upon the dentofacial complexes.<sup>2</sup>

A full-mouth restoration should not be a mystical and difficult undertaking, but rather a methodical, step-by-step procedure. One should pay attention to how nature created the form of the TMJ, the form of the restorations, and

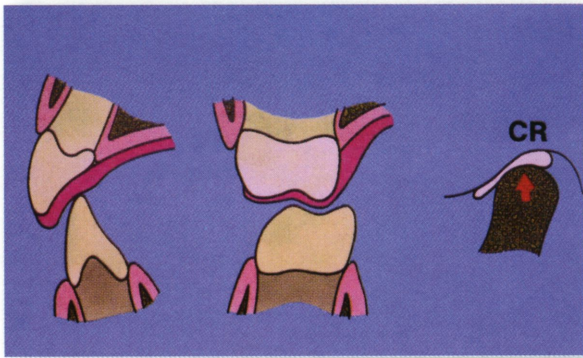
the form of the smile. "Form follows function" or rather, "Form is everything."<sup>3</sup>

The functional goal of a full-mouth rejuvenation is to maximize anterior guidance and verticalize the posterior segment with the normal physiologic position of the condyles in centric relation (CR) (Fig 1). This anterior guidance will allow the technician to develop natural crown forms without eccentric occlusal interferences.<sup>4,5</sup>

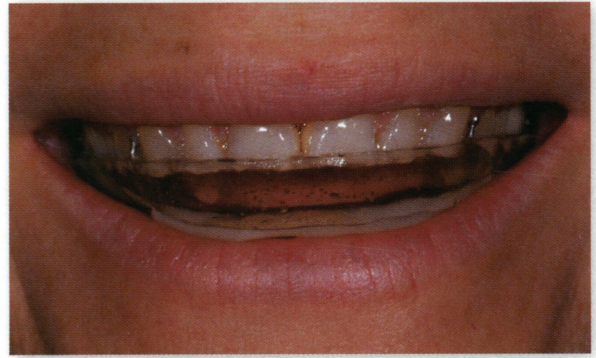The anterior teeth should be long enough to facilitate complete posterior clearance in protrusive guidance. This may be accomplished through proper axial inclination of the anterior teeth and through horizontal overlap of 2 mm and vertical overlap of 3-4 mm (Fig 2).<sup>6,7</sup>

Clinical researchers (Williamson, Lindquist) have found that the elevating activity of the temporal and masseter muscles can be reduced only when posterior disclusion is obtained






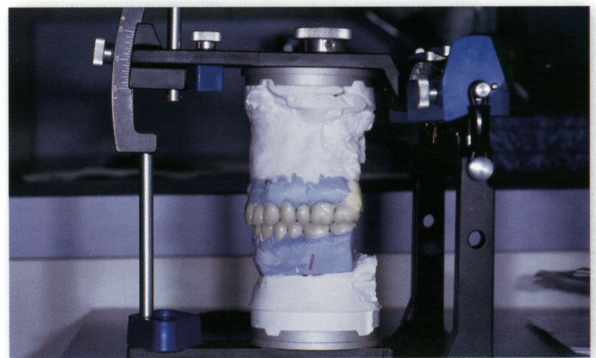
**Figure 5:** The role of the orthosis is to remove all centric and eccentric occlusal interferences and allow the condyles to reach their most superior position.



**Figure 6:** Phase II of condyle repositioning CR orthosis is accomplished by adding posterior occlusal contacts. Periodic adjustments may be necessary.



**Figure 7:** Maxillary anterior guided orthosis.



**Figure 8:** Full contour wax-up converted into provisionals.

with proper anterior guidance. These clinicians believe that the elimination of posterior interferences, rather than canine contacts alone, decreases the activity of the elevator muscles.<sup>8</sup>

## CASE REPORT

A female patient presented with severe wear and loss of vertical dimension, for an extensive diagnosis of her stomatognathic system (Figs 3 & 4).

Diagnostic records consisting of centric bite records, and accurate study models mounted with a facebow transfer, were sent to the lab. A maxillary anterior guided orthosis (MAGO), was constructed to centric relationship, establishing vertical dimension of occlusion to 18 mm from cervical

enamel junction to cervical enamel junction (CEJ), to CEJ.

---

*...it is beneficial for the technician to meet the patient and get a personal image of the face and the smile.*

---

The role of the orthosis is to remove all centric and eccentric occlusal interferences and allow the condyles to reach their most superior position (Fig 5).<sup>3</sup> The patient wore the MAGO 24 hours a day for 1 week at the new VDO (Fig 6.)

No discomfort was reported. Acrylic posterior stops were placed one week later and the patient continued

wearing the splint for an additional 2 weeks without difficulty (Fig 7).

After confirming that a stable CR had been obtained, new models were taken, along with a facebow transfer. The models and data were sent to the laboratory, which then constructed a diagnostic wax-up on centrally mounted casts using an individually adjusted Panadent (Panadent, Inc.; Grand Terrace, CA) articulator. This type of wax-up is one of the most valuable steps in a full-mouth reconstruction process. The wax-up can be used not only for diagnosis, treatment planning, and patient education, but also to form plastic provisional crowns during treatment (Fig 8).



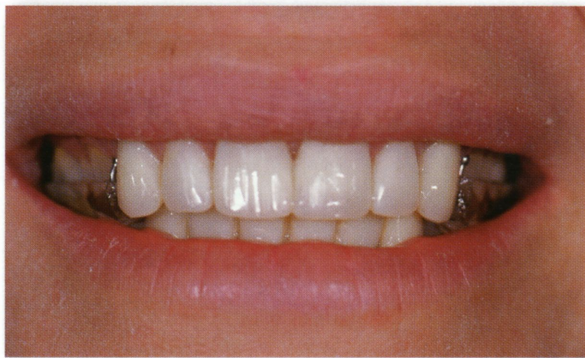

Figure 9: New vertical dimension with anterior provisionals in place.

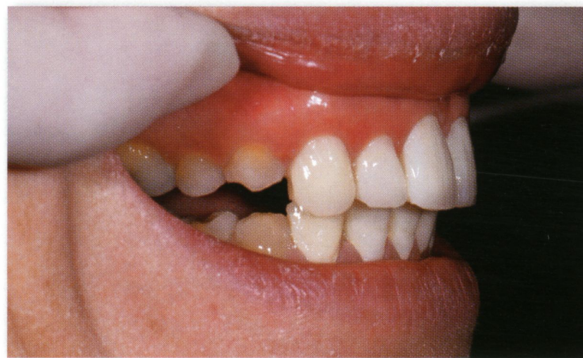

Figure 10: Establishing the smile line with the provisionals.

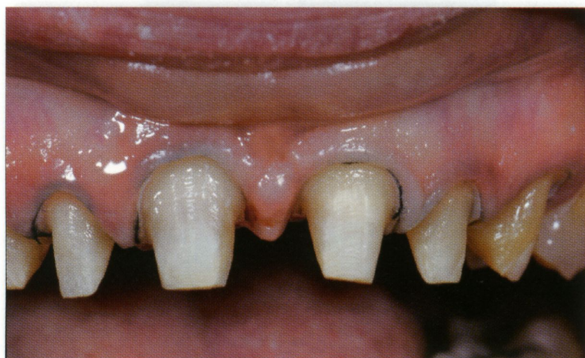

Figure 11: Preps for Procera crowns.

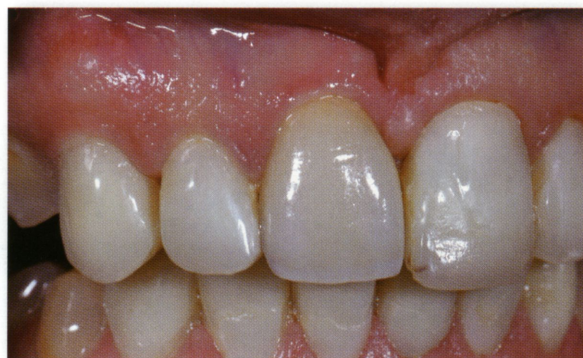

Figure 12: Single color test crown for patient's approval.

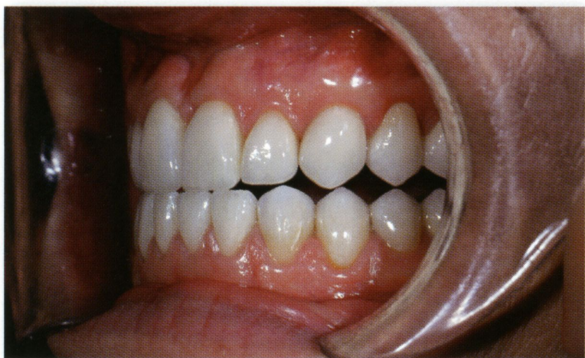

Figure 13: Laterals shorter than centrals to allow the lower cuspids room to pass through in protrusion.

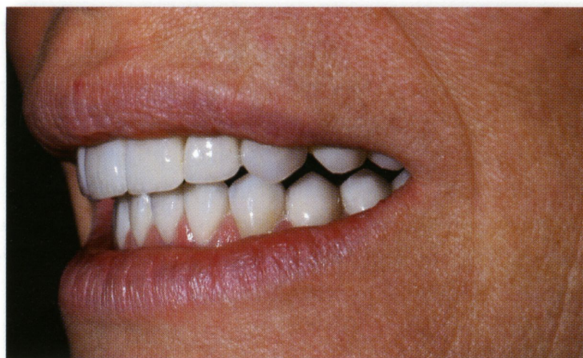

Figure 14: Cuspid guidance to clear all eccentric contact on both balancing and working side.



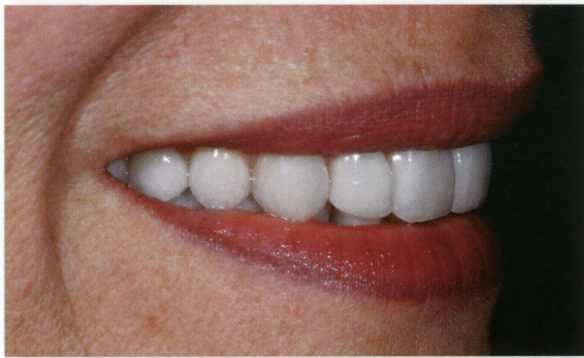

Figure 15: Posterior gradation to follow lip line.

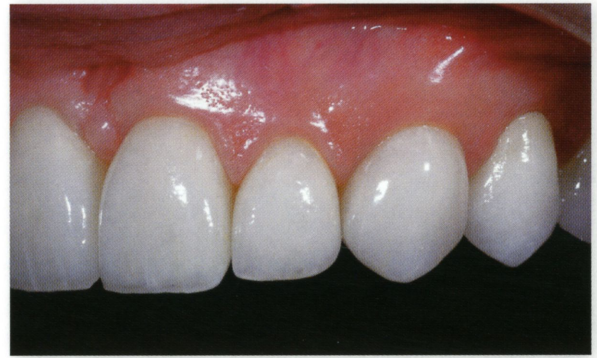
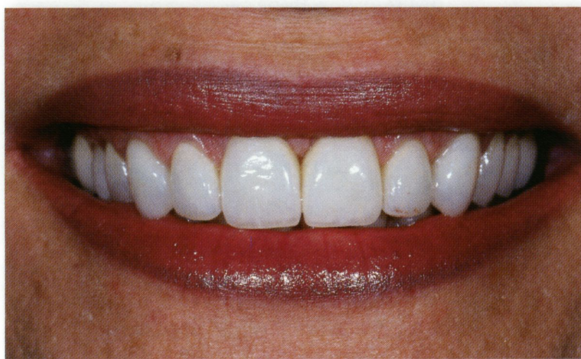
Figure 16: Embrasures progressing from the central incisor to the canine.



Figures 17 & 18: A great smile takes so little time but gives so much.

The dentist now has the opportunity to verify the correct esthetic facial and dental composition, and may add or subtract to provisionals as long as the form and functions are not violated. When the patient is completely satisfied with the form of the provisionals, a set of study models can be recorded for the technician to use as a guideline (Fig 9).

Some patients and clinicians might not be comfortable with prepping all the teeth in one appointment, as was the case with this patient. The clini-

cian altered the MAGO splint by removing the anterior section, thus providing posterior overlay support. The new VDO was confirmed and established with the anterior provisionals. All of the guesswork has been removed and the dentist may now proceed with the posterior restorations (Fig 10).

### LABORATORY

Photographic prints and 35 mm slides were taken for the case; however, it is beneficial for the technician to

meet the patient and get a personal image of the face and smile.<sup>3</sup>

The restoring dentist prepped the teeth for full coverage. Procera (Nobelbiocare; Yorba Linda, CA) copings with Vita Alpha (Vident; Brea, CA) porcelain overlay were used for the restorations (Fig 11). A single "color test" crown was manufactured first, allowing the patient to see what degree of characterization she wanted. She decided on a lighter color with less chroma (Fig 12).



The crowns were fabricated on a Panadent articulator at CR with the predetermined 18 mm CEJ to CEJ. The condylar angle was recorded by the dentist at 42°. The Bennet settings were 1.5 mm.

The suggested tooth lengths for this patient were 11 mm for the maxillary central incisors, 10 mm for the cuspids, 9 mm for the mandibular centrals and lateral incisors, and 10 mm for the mandibular cuspids.

The length of the maxillary laterals was determined to be shorter than the centrals to provide space for the cusp tips of the mandibular canines in protrusion (Fig 13).

The cuspids were made long enough to provide proper canine guidance that would totally disclude the working and the balancing side posteriorly (Fig 14).<sup>10</sup>

The width of the anteriors was determined using the Golden Rule, negative lateral space, and the size of the mouth.<sup>11</sup> The posterior smile line must rise toward the Frankfort Plane, with the cusp tips and the gingival marginal crest converging as we move posteriorly (Fig 15).<sup>3</sup>

The embrasure between the maxillary centrals is about 1 mm, the lateral to the central 2 mm and the lateral to

the cuspid 3 mm. (Fig10) The incisal edges of the maxillary teeth must be parallel to the horizon, and must conform to the lower lip line in a natural smile (Fig 16).<sup>3</sup>

## CONCLUSION

Applying the procedures described above enabled the restoring team to reach a pleasing esthetic and functional result that follows the natural guidelines according to bioesthetic principles (Lee). These procedures are general guidelines that bioesthetically trained dentists usually follow. Sometimes these guidelines are altered slightly to focus on the bottom third of the facial configuration (the lip size and the smile line). By incorporating both esthetic and functional principles this patient will benefit for years to come.

A great smile takes so little effort but gives so much. It brightens the lives of all who receive it, while empowering those who give it (Figs 17 & 18).<sup>1</sup> *Ag*

## Acknowledgement

The author thanks Dr. Larry Addleson, San Diego, for allowing his case to be featured in this article.

## REFERENCES

- Hunt K. Full-mouth multidisciplinary restoration using the biological approach: A case report. *Pract Proced Aesthet Dent* 13(5):399-406, 2001.
- Wheeler, W.B. R.C.A *Textbook of Dental Anatomy and Physiology* (6th ed., 1988; 130, 148, and 161). Philadelphia: Saunders.
- Lee, R.L. Anterior guidance. In Rufenact, C.R. *Fundamentals of Esthetics*. Chicago, IL: Quintessence (1990).
- Rufenacht, C.R. *Fundamentals of Esthetics*. Chicago, IL: Quintessence (1990).
- Stuart, C.E. Why dental restorations should have cusps. *J South Dental Assoc* 21:1998-2000, 1959.
- D'Amico A. The canine teeth: Normal functional relation of the natural teeth of man. *J So Calif Dent Assoc* 26:6-23, 49-60, 127-142, 175-182, 194-208, 239-241, 1959.
- Lee, R.L. Anterior guidance. In Rufenact, C.R. *Fundamentals of Esthetics*. Chicago, IL: Quintessence (1990).
- Williamson, E. et al. Anterior guidance: Its effect on electromyographic activity of the temporal and Masseter muscles. *J Prosthet Dent* 49:816-823, 1983.
- Gallegos, G. Enhancing Interprofessional Communication Through Digital Photography. *CDA Journal* 29(10):752-757, 2001.
- Dawson, P.E. *Evaluation, Diagnosis, and Treatment of Occlusal Problems*. St.Louis: C.V. Mosby (1974).
- Levine, E.L. Dental esthetics and the golden proportion. *J Prosthet Dent* 40:244, 1978.



### GBAS Silent Auction, continued from page 40 ITEMS UP FOR BID

#### VACATION GETAWAYS

- A 2-night stay at the downtown New Orleans Marriott Hotel, donated by New Orleans Marriott
- A 2-night stay for two in classic accommodations, including two rounds of golf each for two people, at The Broadmoor, a 5-star resort, donated by The Broadmoor
- Marriott Gold Weekend Award- Includes one Weekend Night, Breakfast and Dinner for Two, donated by Marriott International
- One United Airlines Certificate, donated by Burkhalter Travel & Cruise Shoppe

- A Weekend Stay for Two at the Atlanta Marriott Marquis, donated by The Atlanta Marriott Marquis

#### DENTAL COURSES

- Doctor and Team Member Tuition to any Program in 2002/2003, donated by genR8TNext
- Tuition to the AACD's 19th Annual Scientific Session in Orlando, Florida in 2003, plus a 2-night stay at the official conference hotel, donated by the American Academy of Cosmetic Dentistry
- \$1000 Gift Certificate to be used towards a Course at The Amara Institute, donated by The Amara Institute
- Course Tuition for "The Digital Patient Consultation" for Doctor,

Two Staff Members, and Spouse, donated by Dallas Dental Solutions

#### DENTAL-RELATED GIFTS

- Contra Disposable Angles, donated by Young Dental
- Image FX 4.0 Specialized Software, donated by SciCan, Inc.
- PoGo™ Starter Kit, donated by Dentsply Caulk
- Esthet-K® East Twist Syringe Kit, donated by Dentsply Caulk
- 2 One Porcelain Veneers, donated by Re-Creations by PUGA
- Optilux 501 Curing Light, donated by Demetron/Kerr Corporation

GBAS Silent Auction, continued on page 70